



Percutaneous Medial Collateral Ligament Repair and Posteromedial Corner Repair With Suture Tape Augmentation

Graeme P. Hopper, M.B.Ch.B., M.Sc., M.R.C.S., Joanne M. Jenkins, M.B.B.S., B.Sc., and Gordon M. Mackay, M.D.

Abstract: The medial collateral ligament (MCL) is among the most commonly injured structures of the knee. Most cases are managed nonoperatively; however, grade III injuries and injuries associated with multiligament injuries to the knee are often managed surgically. MCL reconstruction procedures are the most widely used surgical option, but modern advancements have seen a renewed interest in ligamentous repair that avoids graft-site morbidity. In addition, augmentation of the repair protects the ligament during the healing phase and allows early mobilization. This article describes, with video illustration, percutaneous MCL repair and posteromedial corner repair with suture tape augmentation.

The posteromedial corner of the knee consists of the superficial medial collateral ligament (MCL), deep MCL, posterior oblique ligament, oblique popliteal ligament, and posterior horn of the medial meniscus, with the superficial MCL being the main medial structure as the primary static stabilizer to valgus stress of the knee.^{1,2} The MCL is among the most commonly injured structures of the knee, with most healing occurring with nonoperative management.³⁻⁵ However, grade III injuries or multiligament injuries of the knee are best stabilized surgically.⁶

MCL reconstruction procedures are the most widely used surgical option, and several techniques, graft choices, and fixation methods have been described in the literature with acceptable results.⁷ On the other hand, recent literature has seen a renewed interest in ligamentous repair with or without augmentation with advancements in surgical equipment and increasing knowledge.⁸

In this Technical Note, we describe percutaneous MCL repair with suture tape augmentation that encourages healing and allows early mobilization. In addition, we describe augmentation of the posterior oblique ligament for cases of a severely disrupted posteromedial corner (Video 1).

From the College of Medical, Veterinary and Life Sciences, University of Glasgow (G.P.H.), Glasgow; Department of Trauma and Orthopaedic Surgery, Glasgow Royal Infirmary (J.M.J.), Glasgow; and University of Stirling (G.M.M.), Stirling, Scotland.

The authors report the following potential conflicts of interest or sources of funding: Arthrex facilitated the making of the video of this surgical technique. G.M.M. is a consultant for and receives royalties from Arthrex and has a patent for the InternalBrace. Full ICMJE author disclosure forms are available for this article online, as [supplementary material](#).

Received October 22, 2019; accepted January 3, 2020.

Address correspondence to Graeme P. Hopper, M.B.Ch.B., M.Sc., M.R.C.S., College of Medical, Veterinary and Life Sciences, University of Glasgow, 120 University Place, Glasgow, Scotland G12 8TA. E-mail: graemehopper@nhs.net

© 2020 by the Arthroscopy Association of North America. Published by Elsevier. This is an open access article under the CC BY-NC-ND license (<http://creativecommons.org/licenses/by-nc-nd/4.0/>).

2212-6287/191295

<https://doi.org/10.1016/j.eats.2020.01.008>

Surgical Technique

The patient is placed in the supine position, and a tourniquet is placed on the upper thigh. The injured leg is prepared and draped in the surgeon's preferred position, similarly to any arthroscopic procedure around the knee. Appropriate landmarks are palpated and marked, including the medial epicondyle and a point roughly halfway between the joint line and the pes anserinus (Fig 1).

A stab incision is made over the medial epicondyle. The next step is to predrilling with a 4.5-mm drill and tap just posterior and proximal to the medial epicondyle, ensuring that one remains perpendicular to the cortex. A 4.75-mm SwiveLock (Arthrex) preloaded with FiberTape (Arthrex) is then inserted, ensuring it is

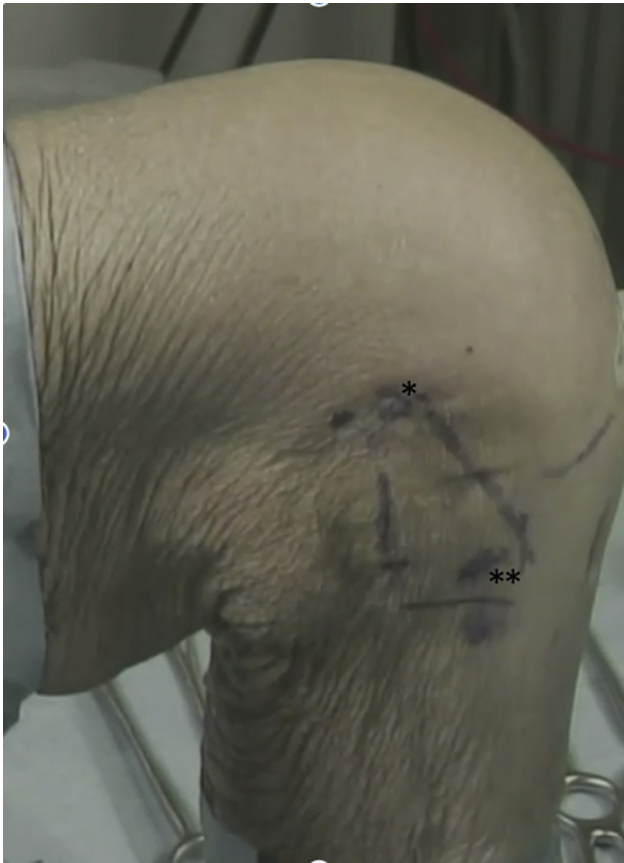

Fig 1. Medial view of left knee. The medial epicondyle (1 asterisk) and the distal insertion site of the medial collateral ligament, roughly halfway between the joint line and the pes anserinus (2 asterisks), are shown.

flush with the cortex to minimize any subcutaneous irritation and to ensure optimal strength of the fixation itself (Fig 2). The FiberTape is an ultrahigh-strength 2-mm-wide tape, consisting of long-chain ultrahigh-molecular-weight polyethylene.

A hemostat is passed subcutaneously to the pre-marked insertion site distally, and a short stab incision is made. The suture that has been removed from the anchor is then used to shuttle the suture tape distally. The insertion point is between the anterior third and posterior two-thirds of the MCL. Preparation is then carried out for a further 4.75-mm anchor by predrilling. The suture tape is wrapped around the drill sleeve to ensure a degree of isometricity, and the knee is taken through a range of motion to make sure the knee is balanced prior to drilling. Tapping is then performed, ensuring to be flush with the cortex. The second 4.75-mm anchor is loaded with the suture tape and placed at the tip of the tap; then, the tape is marked at the laser line, which allows for the length of the anchor itself and prevents any additional tensioning of the

construct during its insertion. Excessive tensioning may be detrimental because it may constrain and compress the medial compartment of the knee. The suture tape is repositioned in the eye of the anchor at the marked level, the knee is taken through a range of motion, and finally, the anchor is placed in the drill hole (Fig 2). The suture tape restores the anatomic length of the MCL, allowing it to heal naturally, and acts as a “seat belt” to prevent any attenuation during the early phases of healing.

In cases of a severely disrupted posteromedial corner,⁹ the posterior oblique ligament can also be augmented. This is an open procedure rather than the percutaneous approach we have described for the MCL. The semimembranosus insertion is identified distally, and the adductor tubercle is identified proximally. Preparation is then carried out for a 4.75-mm anchor proximally by predrilling and tapping. The anchor is inserted with the loaded suture tape, ensuring to be flush with the cortex. The suture tape is secured distally with a further 4.75-mm anchor after loading of the suture tape. Measurement takes place in full extension because the posterior oblique ligament is only taut in this position. A purse-string suture is also used to approximate the soft tissues to the initial suture tape and can be used to rebalance the soft tissues to ensure adequate tension is restored (Fig 3). This encourages natural healing of the ligament at its natural length while providing sufficient strength to support early mobilization.

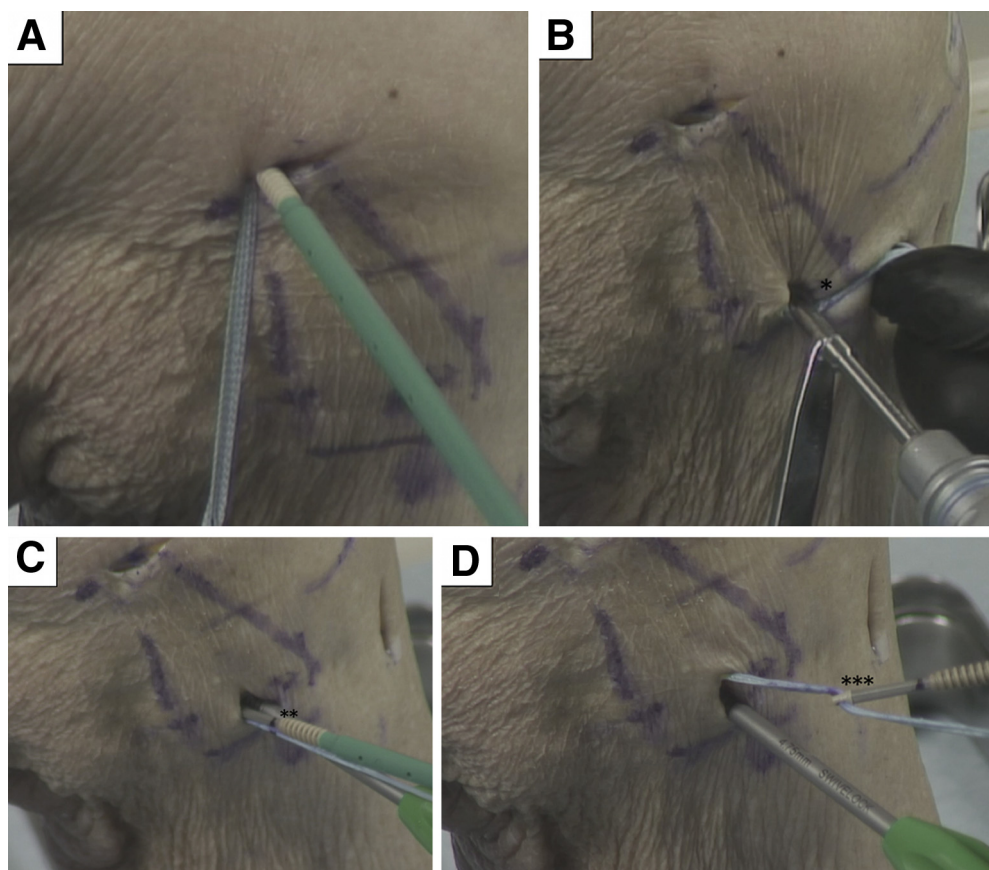
The rehabilitation protocol could be compared with an accelerated MCL reconstruction protocol. Patients are allowed to fully weight bear with crutches as required during the first few weeks. Physical therapy focuses on early range of movement, muscle control, and restoration of function; this is facilitated by the limited pain and swelling, allowing accelerated early-phase rehabilitation. Patients are allowed to perform sports if neuromuscular function has recovered. No brace is required. Advantages and disadvantages of this technique and some pearls and pitfalls are outlined in Tables 1 and 2, respectively.

Discussion

Treatment of medial-sided knee injuries presents a difficult challenge. Although most cases will heal with nonoperative management, grade III injuries and multiligament cases are best treated surgically. MCL reconstruction techniques are the most widely used, and multiple techniques have been described in the literature with acceptable results.⁷ Alternatively, MCL repair techniques have also been described in the literature and have been indicated to be a viable option.⁵

A recent systematic review by Varelas et al.⁷ of 10 studies with 275 knees showed significant

Fig 2. Medial view of left knee. (A) The 4.75-mm anchor that is preloaded with suture tape is inserted proximally. (B) The suture tape is wrapped around the drill sleeve to ensure a degree of isometricity (asterisk). (C) The suture tape is marked at the laser line (asterisks), which allows for the length of the anchor itself and prevents any additional tensioning of the construct during its insertion. (D) The suture tape is repositioned in the eye of the anchor at the marked level (asterisks).



improvement in patient-reported outcomes at a mean follow-up of 33 months after MCL reconstruction. Most cases had multiligament knee injuries, and no differences were seen between concomitant procedures, as well as the array of grafts and techniques used. It is interesting to note that most concomitant MCL injuries occur with anterior cruciate ligament injuries, and combined reconstructions of the anterior cruciate ligament and MCL are associated with increased arthrofibrosis.¹¹ As a result, staged procedures are often indicated.

Posteromedial corner repair was the classical technique for treating medial-sided knee injuries, and an augmentation to this technique would be beneficial.⁹ A number of Technical Notes with similarities to our repair technique with suture augmentation have been described. Lubowitz et al.¹² described the open technique using suture tape augmentation, van Der List and DiFelice¹³ described the repair of a complete proximal avulsion, and Hirahara et al.¹⁰ described a percutaneous technique using ultrasound, which may give some surgeons additional confidence in identifying the bony landmarks. To our knowledge, no clinical outcomes have been published on any of these techniques.

Reassuringly, however, DeLong and Waterman⁵ performed a systematic review of 355 knees to evaluate the clinical outcomes of primary repair of the MCL and posteromedial corner of the knee and concluded that it was an effective and reliable treatment. They reported an improvement in patient-reported outcome scores with a failure rate of 6.1%.

MCL repair with suture tape augmentation as described in this Technical Note reinforces the ligament, acts as a secondary stabilizer, and has a number of advantages over isolated repair and reconstruction techniques. Protection of the MCL by the internal brace during the early postoperative stages promotes natural healing and allows early mobilization. In addition, a graft is not required for the procedure, and percutaneous incisions are used, which avoids any unnecessary surgical morbidity, leading to a quicker recovery. Moreover, a cadaveric biomechanical study by Gilmer et al.³ compared repair alone with internal bracing and reconstruction with allograft and found the internally braced cases were superior to repair alone and comparable to allograft reconstruction. On the other hand, some risks and limitations are associated with this procedure, including the use of synthetic

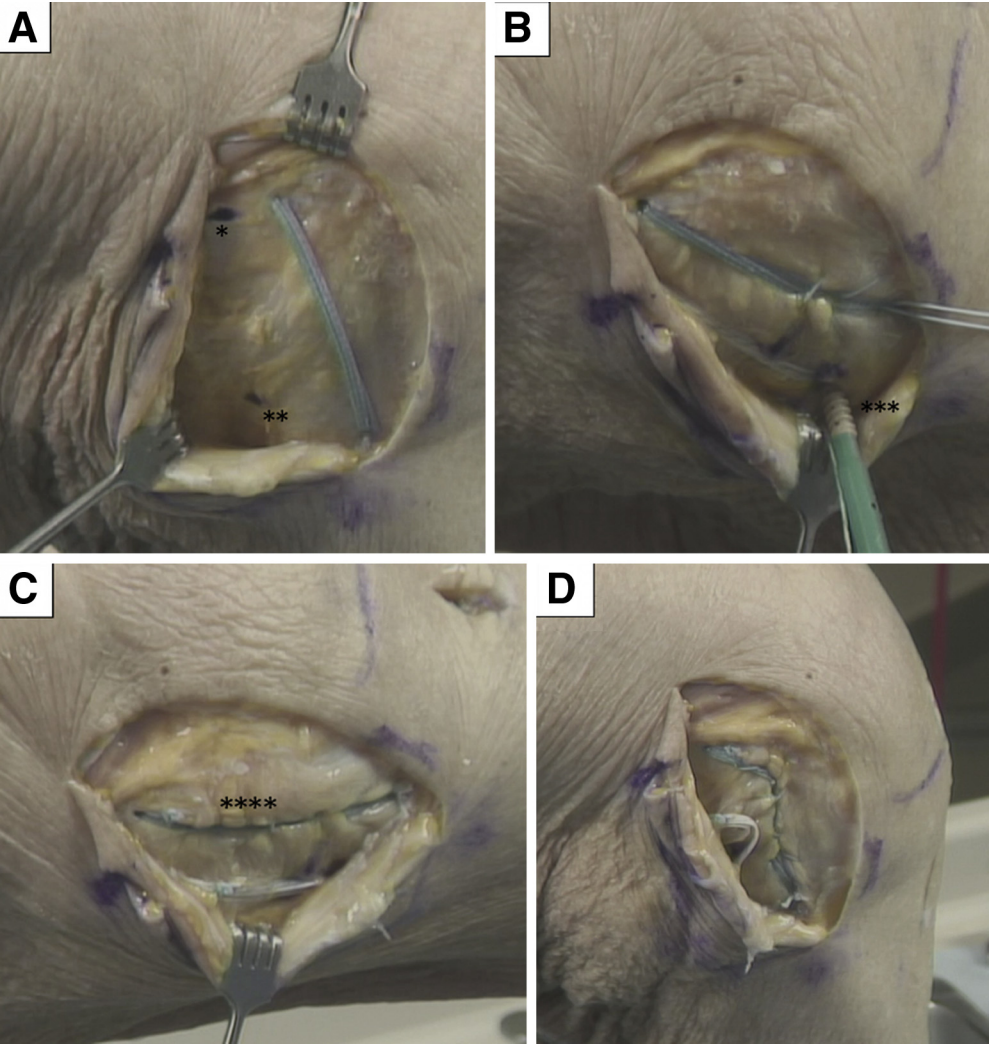


Fig 3. Medial view of left knee. (A) The semi-membranosus insertion is identified distally (1 asterisk), and the adductor tubercle is identified proximally (2 asterisks). (B) The suture tape is secured distally with a 4.75-mm anchor (asterisks) after loading the suture tape. (C) Completed repair. A purse-string suture is used to approximate the soft tissues to the initial suture tape (asterisks). (D) The posterior oblique ligament is only taut in full extension, as shown.

augmentation, excessive tensioning, and medial epicondyle tenderness. As a result, it is important to ensure excessive constraint is not applied because this may compress the medial compartment of the knee.

In conclusion, this Technical Note has discussed the technique of percutaneous MCL repair with suture tape

augmentation including the potential for posterior oblique ligament repair with suture tape augmentation. This is a simple and reproducible technique with minimal surgical morbidity as outlined earlier. Despite this, clinical studies are necessary to determine the overall outcomes of this procedure.

Table 1. Advantages and Disadvantages of Medial Collateral Ligament Repair With Suture Tape Augmentation	
Advantages	
Simple and reproducible	
No graft harvest required	
Facilitates rehabilitation	
Minimal surgical morbidity	
Disadvantages	
Synthetic augmentation	
Medial epicondyle tenderness	
Reliance on biological healing	

Table 2. Pearls and Pitfalls of Medial Collateral Ligament Repair With Suture Tape Augmentation	
Pearls	
The use of ultrasound may give some surgeons additional confidence when identifying the medial epicondyle. ¹⁰	
The surgeon should ensure that excessive constraint is not applied. A purse-string suture can be used to approximate the soft tissues to the initial suture tape to rebalance the soft tissues, ensuring that adequate tension is restored in open cases.	
Pitfalls	
It is important to establish anatomic accuracy.	
Excessive tensioning may constrain and compress the medial compartment of the knee.	

References

1. Cinque ME, Chahla J, Kruckeberg BM, DePhillipo NN, Moatshe G, LaPrade RF. Posteromedial corner knee injuries: Diagnosis, management, and outcomes: A critical analysis review. *JBJS Rev* 2017;5:e4.
2. Andrews K, Lu A, Mckean L, Ebraheim N. Review: Medial collateral ligament injuries. *J Orthop* 2017;14:550-554.
3. Gilmer BB, Crall T, DeLong J, Kubo T, Mackay G, Jani SS. Biomechanical analysis of internal bracing for treatment of medial knee injuries. *Orthopedics* 2016;39:e532-e537.
4. Wijdicks CA, Ewart DT, Nuckley DJ, Johansen S, Engebretsen L, LaPrade RF. Structural properties of the primary medial knee ligaments. *Am J Sports Med* 2010;38:1638-1646.
5. DeLong JM, Waterman BR. Surgical repair of medial collateral ligament and posteromedial corner injuries of the knee: A systematic review. *Arthroscopy* 2015;31:2249-55.e5.
6. Levy BA, Dajani KA, Whelan DB, et al. Decision making in the multiligament-injured knee: an evidence-based systematic review. *Arthroscopy* 2009;25:430-438.
7. Varelas AN, Erickson BJ, Cvetanovich GL, Bach BR. Medial collateral ligament reconstruction in patients with medial knee instability: A systematic review. *Orthop J Sports Med* 2017;5:2325967117703920.
8. Mackay GM, Blyth MJ, Anthony I, Hopper GP, Ribbans WJ. A review of ligament augmentation with the InternalBrace: The surgical principle is described for the lateral ankle ligament and ACL repair in particular, and a comprehensive review of other surgical applications and techniques is presented. *Surg Technol Int* 2015;26:239-255.
9. Hughston JC. The importance of the posterior oblique ligament in repairs of acute tears of the medial ligaments in knees with and without an associated rupture of the anterior cruciate ligament. Results of long-term follow-up. *J Bone Joint Surg Am* 1994;76:1328-1344.
10. Hirahara AM, Mackay G, Andersen WJ. Ultrasound-guided suture tape augmentation and stabilization of the medial collateral ligament. *Arthrosc Tech* 2018;7:e205-e210.
11. Grant JA, Tannenbaum E, Miller BS, Bedi A. Treatment of combined complete tears of the anterior cruciate and medial collateral ligaments. *Arthroscopy* 2012;28:110-122.
12. Lubowitz JH, MacKay G, Gilmer B. Knee medial collateral ligament and posteromedial corner anatomic repair with internal bracing. *Arthrosc Tech* 2014;3:e505-e508.
13. van der List JP, DiFelice GS. Primary repair of the medial collateral ligament with internal bracing. *Arthrosc Tech* 2017;6:e933-e937.