

Anterior Talofibular Ligament Repair With Suture Tape Augmentation



Graeme P. Hopper, M.B.Ch.B., M.Sc., M.R.C.S., Daniel M. Benson, M.B.Ch.B., M.R.C.S.,
William T. Wilson, M.B.Ch.B., B.Sc., M.R.C.S., M.F.S.E.M.,
Ryan B. Rigby, D.P.M., F.A.C.F.A.S., and Gordon M. Mackay, M.D.

Abstract: The most common injury sustained to the ankle ligaments is a result of inversion of the foot. This mechanism results in injury to the anterior talofibular ligament alone or in conjunction with the calcaneofibular ligament and posterior talofibular ligament. Patients experiencing recurrent ankle sprains despite nonoperative measures often require surgical management. Recent focus has been on augmentation procedures to improve the stability of a lateral ankle ligament repair by protecting it during the healing phase and supporting early mobilization. This article describes, with video illustration, anterior talofibular ligament repair with suture tape augmentation.

Introduction (With Video Illustration)

The anterior talofibular ligament (ATFL) originates at the anterior margin of the lateral malleolus and runs anteromedially to its insertion on the talar body. It limits anterior displacement and is the primary restraint to inversion when the ankle is in plantar flexion. The calcaneofibular ligament (CFL) originates from the anterior part of the lateral malleolus and runs obliquely to insert into the lateral calcaneum. It is the primary restraint to inversion when the ankle is in a neutral or dorsiflexed position. The posterior talofibular ligament originates on the medial surface of the lateral malleolus and crosses horizontally to its insertion on the

posterolateral talus. It has a supplementary role in ankle instability, limiting posterior talar displacement.¹

In total, 85% of all ankle sprains involve the lateral ankle ligaments and approximately 10% to 20% of these patients will experience recurrent sprains.^{2,3} Chronic ankle instability can lead to altered kinematics and degenerative changes in the ankle.⁴⁻⁷ As a result, patients experiencing recurrent ankle sprains despite nonoperative measures often require surgical management.

Broström⁸ described an anatomical repair of the ATFL in 1966, and this has been considered the standard surgical management for patients with chronic lateral ankle instability. Several modifications with varying success have been described in the literature.^{9,10} However, a number of concerns have arisen with the Broström

From the College of Medical, Veterinary and Life Sciences, University of Glasgow (G.P.H., D.M.B.) and Department of Biomedical Engineering, University of Strathclyde (W.T.W.), Glasgow, Scotland; Logan Regional Orthopaedics, Logan, Utah, U.S.A. (R.B.R.); and University of Stirling, Stirling, Scotland (G.M.M.).

The authors report the following potential conflicts of interest or sources of funding: Arthrex has facilitated the making of the video of this surgical technique. G.M.M. is a consultant for, and receives royalties from, Arthrex. He also has a patent for the internalBrace. Full ICMJE author disclosure forms are available for this article online, as [supplementary material](#).

Received May 26, 2020; accepted August 10, 2020.

Address correspondence to Graeme P. Hopper, M.B.Ch.B., M.Sc., M.R.C.S., College of Medical, Veterinary and Life Sciences, University of Glasgow, 120 University Place, Glasgow, Scotland G12 8TA. E-mail: graemehopper@nhs.net

© 2020 by the Arthroscopy Association of North America. Published by Elsevier. This is an open access article under the CC BY-NC-ND license (<http://creativecommons.org/licenses/by-nc-nd/4.0/>).

2212-6287/201034

<https://doi.org/10.1016/j.eats.2020.08.016>

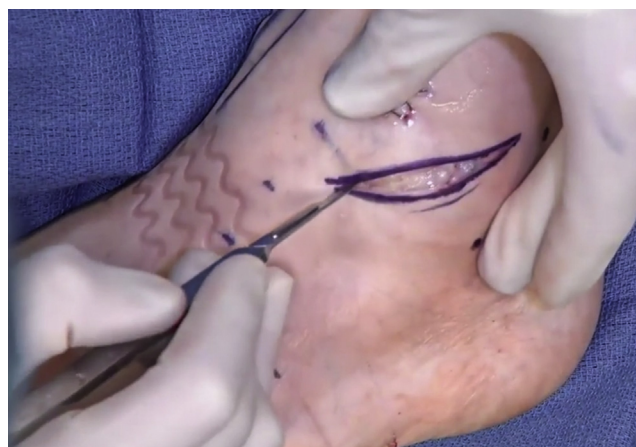

Fig 1. Left ankle, lateral view. Careful dissection of the subcutaneous tissues and hemostasis is achieved.

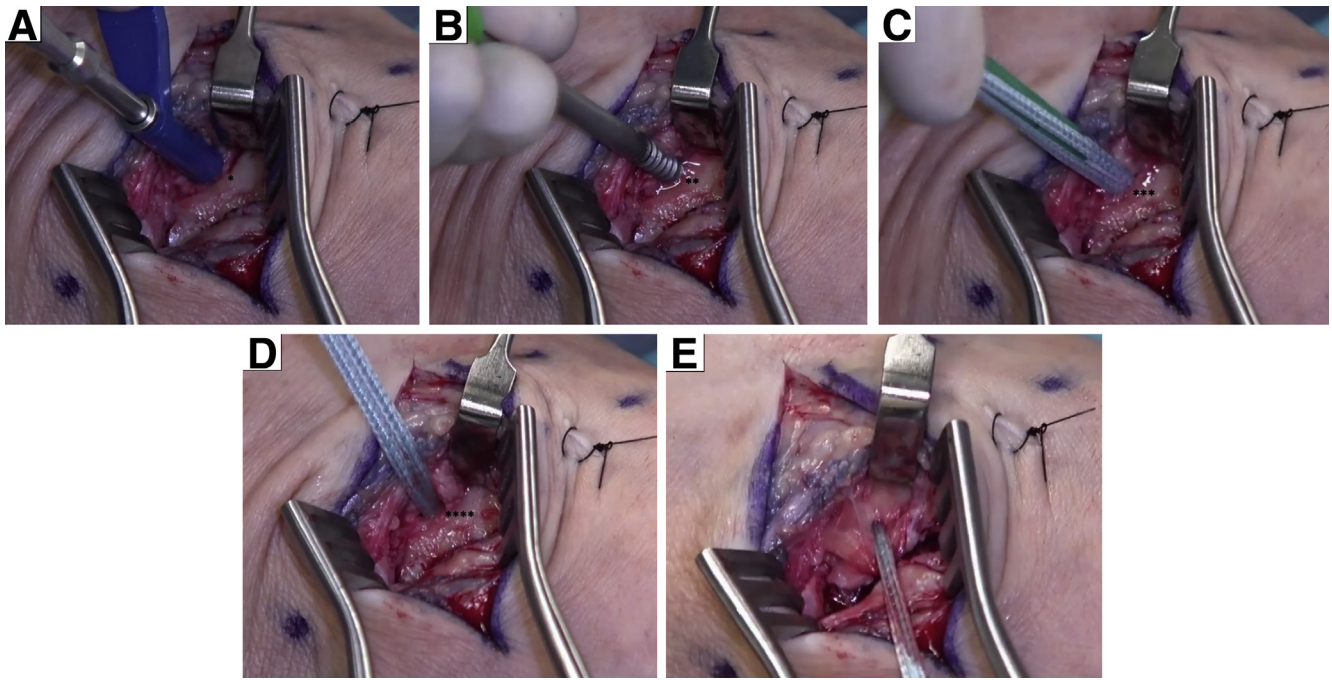


Fig 2. Left ankle, lateral view. (A) A drill guide is applied at 45° medial and parallel to the floor with the foot and ankle in neutral to avoid entering the sinus tarsi or ankle joint (*). (B) The drill hole is then tapped with a 4.75-mm tap (**). (C) The 4.75 bone anchor is then inserted until flush with bone (***). (D) The suture tape can then be used as a retractor (****). (E) The preloaded sutures allow the midpoint of the ATFL to be identified and the suture is then passed so that the internal brace is mirroring normal anatomy. (ATFL, anterior talofibular ligament.)

repair, in particular its failure to restore biomechanical strength.¹¹⁻¹⁴ In addition, postoperative instability has been reported, with increased rates in some patient populations including professional athletes.¹⁵⁻¹⁷

As a result, recent focus has been on augmentation procedures to improve the stability of the lateral ankle ligament repair by acting as a secondary stabilizer.¹⁸ In this Technical Note we describe ATFL repair with suture tape augmentation, which protects the ligament during the healing phase and allows early mobilization (Video 1).

Surgical Technique

The patient is placed in the supine position and a tourniquet is placed on the upper thigh or calf according to surgeon's and patient's preference. The leg is prepared and draped in the surgeon's preferred position similar to any procedure around the ankle. If any intra-articular pathology has been identified preoperatively, then an ankle arthroscopy is undertaken before the ATFL repair.

Appropriate landmarks are palpated and marked, including the outline of the fibula and the course of the superficial peroneal and sural nerves. Careful dissection of the subcutaneous tissues follows and hemostasis is achieved (Fig 1).

The inferior extensor retinaculum is then identified and separated from the underlying talocrural capsule, ATFL, and CFL. This provides a tissue plane for passage

of the suture tape if required. The capsule and ATFL are separated from the fibula in a curvilinear fashion, with care taken not to make the incision too distal, as adequate tissue length is required for repair. In addition, care must be taken when dissecting anteriorly to avoid the superficial peroneal nerve.

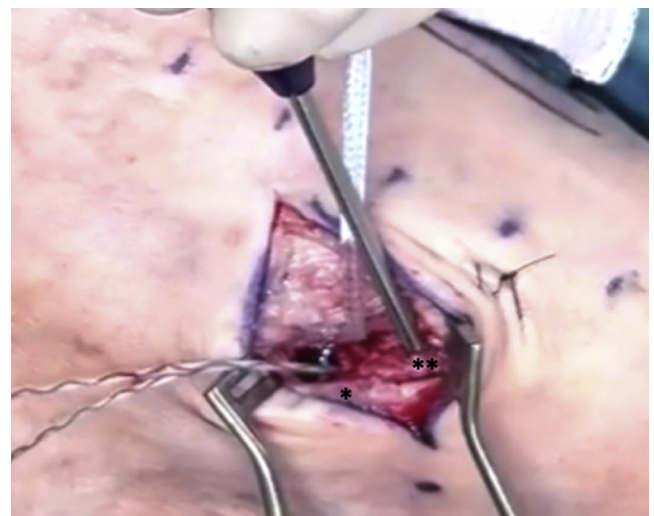
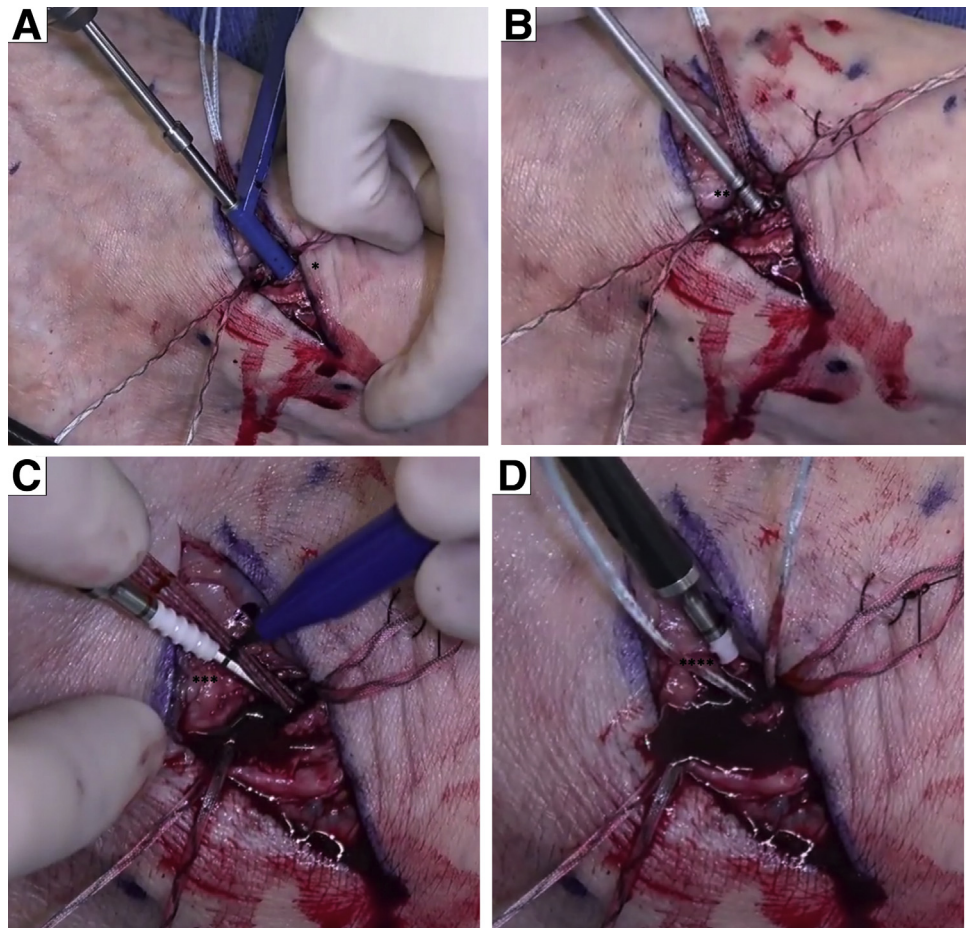


Fig 3. Left ankle, lateral view. With a 1.35-mm Kirschner wire 1 cm from the tip of the fibula, the bone anchor can be inserted with gentle taps until the laser line is flush with bone (*). At 1 cm proximal to this, the superior bone anchor is inserted (**).

Fig 4. Left ankle, lateral view. (A) Midway between the bone anchors at the edge of the anterior wall and the lateral surface of the fibula, a drill hole is made with the 3.5-mm drill (*). (B) This is then fully tapped (**) and (C) the appropriate depth and tension mark are measured at the laser line (***). (D) A 3.5-mm bone anchor preloaded with suture tape is then inserted until flush with the bone (****). The paddle is then turned clockwise, and the anchor is deployed.



The insertion point of the ATFL on the non-articulating surface of the lateral border talus is identified. A drill guide is applied at 45° medial and parallel to the floor with the foot and ankle in neutral to avoid entering the sinus tarsi or ankle joint. The drill hole is then tapped with a 4.75-mm tap. The 4.75-mm SwiveLock (Arthrex, Naples, FL) anchor is then inserted until flush with bone (Fig 2).

The preloaded sutures allow the midpoint of the ATFL to be identified and the suture is then passed so that the internal brace is mirroring normal anatomy. Once passed, the FiberTape (Arthrex) can then be used as a retractor and attention focused on the Broström repair itself (Fig 2). The suture tape is an ultra-high strength 2-mm width tape consisting of a long chain ultra-high molecular weight polyethylene.

With a 1.35-mm Kirschner wire 1 cm from the tip of the fibula, the DX Fibertak (Arthrex) anchor can be inserted with gentle taps until the laser line is flush with bone. The anchor, which is loaded with 2-0 FiberWire (Arthrex), is then secured within the bone by giving it a sharp pull, which allows bunching of the

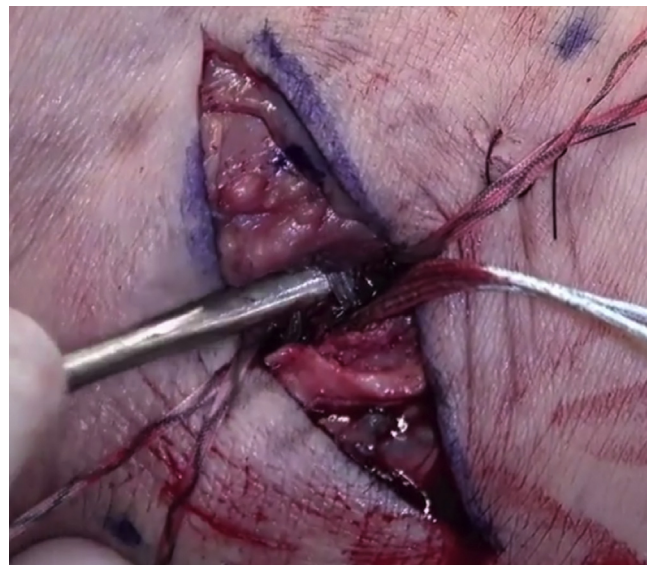

Fig 5. Left ankle, lateral view. The length and tension of the suture tape is determined by placing a hemostat underneath the suture tape before anchor tightening with the ankle in neutral to avoid over constraining the joint.

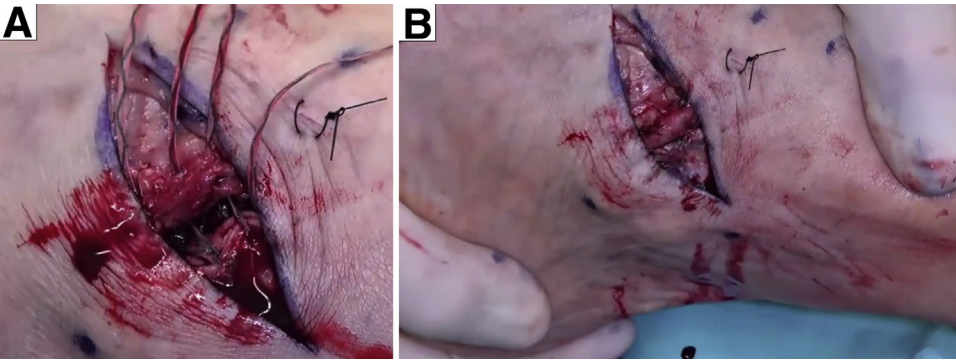


Fig 6. Left ankle, lateral view. (A) The free proximal edges of the inferior extensor retinaculum can be sutured to the capsule followed by a standard superficial closure. (B) The ankle is taken through a range of motion to assess ankle stability.

fibers within the bone. At 1 cm proximal to this, on the anterior aspect of the fibula, the process is repeated, allowing for secure fixation of the lateral ligament complex. The superior anchor secures primarily the ATFL whereas the inferior anchor secures the CFL if required (Fig 3).

The distal fibula is prepared with a rasp to enhance healing following the ATFL repair. The CFL is inspected. A 3.5-mm bone anchor preloaded with suture tape is then inserted (Fig 4). The length and tension of the suture tape is determined by placing a hemostat underneath the suture tape before anchor tightening with the ankle in neutral to avoid overconstraining the joint (Fig 5).

The ankle is then taken through a range of motion and ankle stability is confirmed. Finally, the free proximal edges of the inferior extensor retinaculum can be sutured to the capsule followed by a standard superficial closure (Fig 6).

Patients are allowed to weight bear as comfort allows in a removable boot for the first few weeks postoperatively. Return to sports is assessed individually but is usually 8 to 12 weeks postoperatively. Advantages and disadvantages of this technique as well as some pearls and pitfalls are outlined in Tables 1 and 2.

Table 1. Advantages and Disadvantages of ATFL Repair With Suture Tape Augmentation

| Advantages | Disadvantages |
|---|---|
| Standard approach | Relies on strength of soft tissues and suture |
| Minimally invasive with a low surgical morbidity | Anchor may fracture or loosen (particularly in cancellous bone) |
| Internal brace mirrors normal anatomy | |
| Suture tape provides robust fixation and load sharing | |
| Early mobilization and rehabilitation | |
| No graft harvest required | |

ATFL, anterior talofibular ligament.

Discussion

The most common injury sustained to the ankle ligaments is a result of inversion of the foot. Although the majority of these injuries can be managed conservatively with peroneal muscle strengthening, physiotherapy, and external bracing as to prevent repeat injury, approximately 20% of these patients will go on to develop chronic ankle instability.^{2,3} These patients may be eligible for an ATFL repair.

The widely used Broström technique has been criticized for not restoring biomechanical strength and patient’s suffering from postoperative instability.¹⁵⁻¹⁷ The technique we have described has overcome these issues by restoring normal anatomy as well as providing a robust and load-sharing fixation.

The use of suture tape as described in this Technical Note acts to augment the strength of the ligament by acting as a secondary stabilizer. This facilitates natural healing during the healing process and allows early mobilization for the patient. Moreover, there is no requirement for tendon harvest, which reduces surgical morbidity and recovery time. However, this technique does rely on there being sufficient tissue for ligament fixation.

In a recent clinical study, female patients who suffered from mechanical ankle instability underwent an ATFL repair with suture tape augmentation. During a follow-up period of 2 years, 91.2% of these patients

Table 2. Pearls and Pitfalls of ATFL Repair With Suture Tape Augmentation

| Pearls | Pitfalls |
|---|--|
| Retract lateral ligament with drill guide for initial anchor insertion | Avoid securing in dorsiflexion |
| Suture tape can be used as a retractor allowing easy access for Broström repair | Insert suture anchor gently, as this can damage the threads of the screw or lead to fracture |
| Sharp pull on the suture anchor firmly secures within bone | Malposition of fixation points can constrain the joint |

ATFL, anterior talofibular ligament.

achieved satisfactory functional outcomes.¹⁹ Other studies have shown hastened recovery and rehabilitation with early return to usual activities and sports.²⁰

As previously discussed, the procedure relies on there being enough tissue for ligament fixation. There is also the possibility of progressive elongation over time.¹⁹ It has been suggested that this could represent a possible advantage, as it allows the natural tissues to progressively strengthen.¹² It is therefore vital to assess the longevity of mechanical ankle stability, and until now there have been no long-term follow-up data available to understand the potential effects and side effects.

In conclusion, this Technical Note has discussed the technique of ATFL repair with suture tape augmentation. This is a simple and reproducible technique with minimal surgical morbidity as outlined herein. Despite this, clinical studies are necessary to determine the overall outcomes of this procedure.

References

- Golanó P, Vega J, de Leeuw PA, et al. Anatomy of the ankle ligaments: A pictorial essay. *Knee Surg Sports Traumatol Arthrosc* 2016;24:944-956.
- Gerber JP, Williams GN, Scoville CR, Arciero RA, Taylor DC. Persistent disability associated with ankle sprains: A prospective examination of an athletic population. *Foot Ankle Int* 1998;19:653-660.
- Ferran NA, Maffulli N. Epidemiology of sprains of the lateral ankle ligament complex. *Foot Ankle Clin* 2006;11:659-662.
- Hirose K, Murakami G, Minowa T, Kura H, Yamashita T. Lateral ligament injury of the ankle and associated articular cartilage degeneration in the talocrural joint: Anatomic study using elderly cadavers. *J Orthop Sci* 2004;9:37-43.
- Caputo AM, Lee JY, Spritzer CE, et al. In vivo kinematics of the tibiotalar joint after lateral ankle instability. *Am J Sports Med* 2009;37:2241-2248.
- Harrington KD. Degenerative arthritis of the ankle secondary to long-standing lateral ligament instability. *J Bone Joint Surg Am* 1979;61:354-361.
- Valderrabano V, Hintermann B, Horisberger M, Fung TS. Ligamentous posttraumatic ankle osteoarthritis. *Am J Sports Med* 2006;34:612-620.
- Broström L. Sprained ankles. VI. Surgical treatment of "chronic" ligament ruptures. *Acta Chir Scand* 1966;132:551-565.
- Maffulli N, Ferran NA. Management of acute and chronic ankle instability. *J Am Acad Orthop Surg* 2008;16:608-615.
- Gould N, Seligson D, Gassman J. Early and late repair of lateral ligament of the ankle. *Foot Ankle* 1980;1:84-89.
- Brown CA, Hurwit D, Behn A, Hunt KJ. Biomechanical comparison of an all-soft suture anchor with a modified Broström-Gould suture repair for lateral ligament reconstruction. *Am J Sports Med* 2014;42:417-422.
- Giza E, Whitlow SR, Williams BT, et al. Biomechanical analysis of an arthroscopic Broström ankle ligament repair and a suture anchor-augmented repair. *Foot Ankle Int* 2015;36:836-841.
- Waldrop NE, Wijdicks CA, Jansson KS, LaPrade RF, Clanton TO. Anatomic suture anchor versus the Broström technique for anterior talofibular ligament repair: A biomechanical comparison. *Am J Sports Med* 2012;40:2590-2596.
- Viens NA, Wijdicks CA, Campbell KJ, LaPrade RF, Clanton TO. Anterior talofibular ligament ruptures, part 1: Biomechanical comparison of augmented Broström repair techniques with the intact anterior talofibular ligament. *Am J Sports Med* 2014;42:405-411.
- Schenck RC, Coughlin MJ. Lateral ankle instability and revision surgery alternatives in the athlete. *Foot Ankle Clin* 2009;14:205-214.
- Sammarco GJ, Carrasquillo HA. Surgical revision after failed lateral ankle reconstruction. *Foot Ankle Int* 1995;16:748-753.
- Kuhn MA, Lippert FG. Revision lateral ankle reconstruction. *Foot Ankle Int* 2006;27:77-81.
- Mackay GM, Blyth MJ, Anthony I, Hopper GP, Ribbans WJ. A review of ligament augmentation with the InternalBrace™: The surgical principle is described for the lateral ankle ligament and ACL repair in particular, and a comprehensive review of other surgical applications and techniques is presented. *Surg Technol Int* 2015;26:239-255.
- Cho BK, Park KJ, Kim SW, Lee HJ, Choi SM. Minimal invasive suture-tape augmentation for chronic ankle instability. *Foot Ankle Int* 2015;36:1330-1338.
- Yoo JS, Yang EA. Clinical results of an arthroscopic modified Brostrom operation with and without an internal brace. *J Orthop Traumatol* 2016;17:353-360.