

## Anterior Cruciate Ligament Repair Using Independent Suture Tape Reinforcement



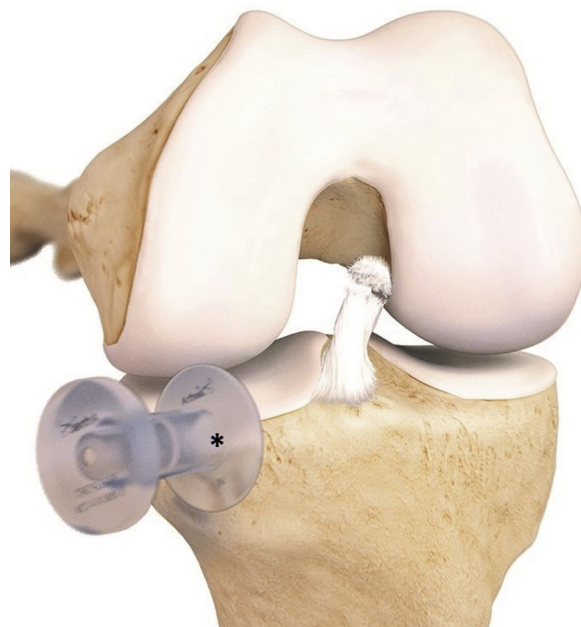
Christiaan H. W. Heusdens, M.D., Graeme P. Hopper, Mb.Ch.B., M.Sc., M.R.C.S.,  
Lieven Dossche, M.D., and Gordon M. Mackay, M.D.

**Abstract:** Recently there has been renewed interest in primary repair of the anterior cruciate ligament (ACL). Repair of the acute proximal ruptured ACL can be achieved with the independent suture tape reinforcement ACL repair technique. The independent suture tape reinforcement technique reinforces the ligament as a secondary stabilizer, encouraging natural healing of the ligament by protecting it during the healing phase and supporting early mobilization. The purpose of this article is to describe, with video illustration, this ACL repair technique.

**A**nterior cruciate ligament (ACL) rupture is a common sports-related injury. ACL reconstruction has been the gold standard for the operative treatment of an ACL rupture for many years. However, only 63% to 65% of the patients return to their pre-injury sport level, and 10.3% have a graft failure after 10 years.<sup>1</sup> Moreover, ACL reconstruction does not protect patients from developing osteoarthritis. Therefore, there has been renewed interest in primary repair of the ACL.<sup>2</sup>

The independent suture tape reinforcement (ISTR) technique for ACL repair consists of an ultra-high-strength 2-mm-wide tape that bridges the ligament and is fixed on the femur with a button and a knotless bone anchor on the tibia. A looped wire holds the distal ACL stump to its femoral attachment. This technique reinforces the ligament as a secondary stabilizer,

encouraging natural healing of the ligament by protecting it during the healing phase and supporting early mobilization.<sup>3</sup>



**Fig 1.** Left knee frontal view. Standard anterolateral and anteromedial portals are created, and arthroscopic inspection of the knee is performed. If necessary, meniscal or cartilage surgery is undertaken. Proximal ruptures of the anterior cruciate ligament are repaired with the independent suture tape reinforcement technique. The anterior cruciate ligament remnant is left intact and not shaved. A flexible arthroscopic cannula (\*) is placed in the anteromedial portal to facilitate the suture management and prevent interposing tissue. This image provided courtesy of Arthrex, Inc. © 2018.

From Antwerp University Hospital (C.H.W.H., L.D.), Edegem, Belgium; Institute of Infection, Immunity and Inflammation, University of Glasgow (G.P.H.), Glasgow; and University of Stirling (G.M.M.), Stirling, Scotland.

The authors report the following potential conflicts of interest or sources of funding: L.D. is a consultant for Mathys. G.M.M. is a consultant for Arthrex and holds a patent for InternalBrace. Full ICMJE author disclosure forms are available for this article online, as [supplementary material](#).

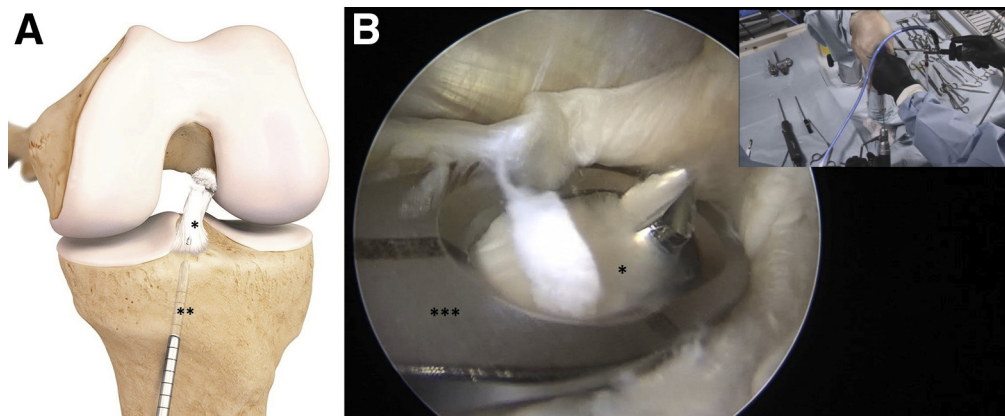
Received December 19, 2017; accepted March 16, 2018.

Address correspondence to Christiaan H. W. Heusdens, M.D., University of Antwerpen, Wilrijkstraat 10, 2650, Edegem, Belgium. E-mail: [krik.heusdens@uza.be](mailto:krik.heusdens@uza.be)

© 2018 by the Arthroscopy Association of North America. Published by Elsevier. This is an open access article under the CC BY-NC-ND license (<http://creativecommons.org/licenses/by-nc-nd/4.0/>).

2212-6287/171537

<https://doi.org/10.1016/j.eats.2018.03.007>



**Fig 2.** (A) Left knee frontal view. This image provided courtesy of Arthrex, Inc. © 2018. (B) Left cadaver knee, intra-articular view on the anterior cruciate ligament (ACL) stump. At the center of the ACL footprint (\*), a standard tibial ACL guide (\*\*\*) is placed at 60° and the tibial tunnel (\*\*) is drilled. The drill is manually advanced (not drilled) through the distal part of the center of the ACL stump.

### Indication

In the case of an acute (within 3 months) ruptured ACL, we start with an arthroscopic inspection of the ruptured ACL. If the ACL is ruptured proximally and the tissue is not retracted and of good quality, the ISTR ACL repair is performed. Otherwise, the procedure is intraoperatively converted to a standard ACL reconstruction.

### Positioning

The patient is placed in the supine position, and a tourniquet is placed on the upper thigh. The injured leg is prepared and draped in the surgeon's preferred position similar to the ACL reconstruction procedure.

### Surgical Technique

#### ACL Inspection

Standard anterolateral and anteromedial portals are created, and arthroscopic inspection of the knee is performed. A PassPort cannula (Arthrex, Naples, FL) is placed in the anteromedial portal, to facilitate the suture management and prevent interposing tissue. If necessary, meniscal or cartilage surgery is performed.

The ACL is inspected. Proximal ruptures of the ACL are repaired with the ISTR technique. The ACL remnant is left intact and not shaved. If the rupture is midsubstance or distal, or the ACL remnant is retracted or of poor quality, a standard ACL reconstruction is performed (Fig 1).

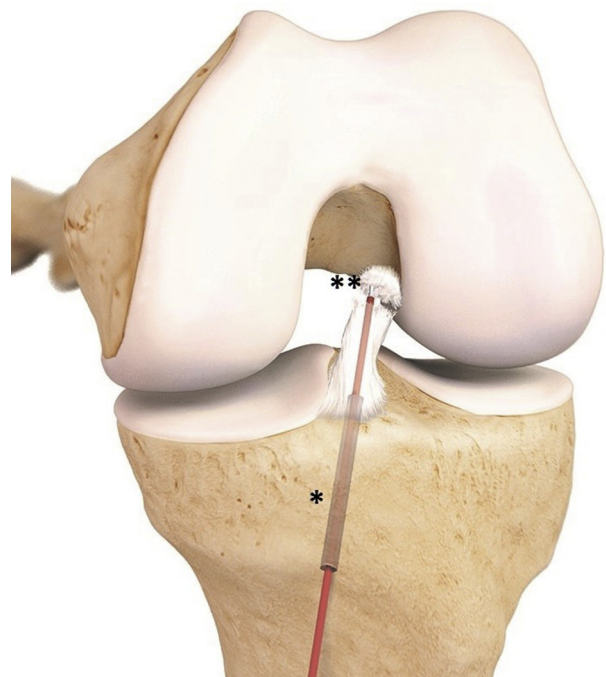
#### Tibial Tunnel

A standard tibial ACL guide is placed at 60° at the center of the ACL footprint. A skin incision is made above the pes anserinus, and a 3.5-mm tibial tunnel is drilled, just passing through the tibial cortex at the ACL footprint. To prepare the tract through the ACL for the high-strength tape, the drill is manually advanced (not drilled) through the distal part of the center of the ACL stump (Fig 2). The drill sleeve is tapped in the anterior

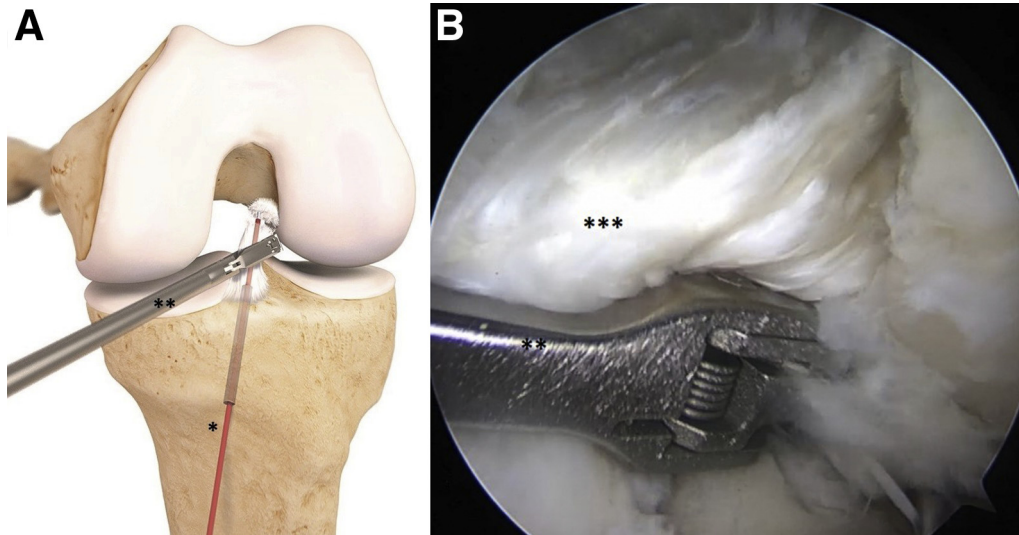
tibial cortex, and the drill is switched for a tubed shuttle wire (FiberStick; Arthrex). The shuttle wire is grasped out of the tube with a suture grasper. The tube is left in place until the shuttle wire suture is brought through the medial portal, taking care to prevent the shuttle wire from cutting through the ACL stump (Fig 3).

#### ACL Suture

The lasso end of a looped wire (FiberLink; Arthrex) is placed over the end of a suture passer (Scorpion; Arthrex) and loaded on the suture passer. The looped wire is passed through the midsubstance of the ACL



**Fig 3.** Left knee frontal view. A tubed shuttle wire (\*) to advance a single shuttle wire (\*\*) is placed through the tibia tunnel and through the anterior cruciate ligament stump. The tubed shuttle wire is left in this position to prevent the shuttle wire cutting through the anterior cruciate ligament stump. This image provided courtesy of Arthrex, Inc. © 2018.



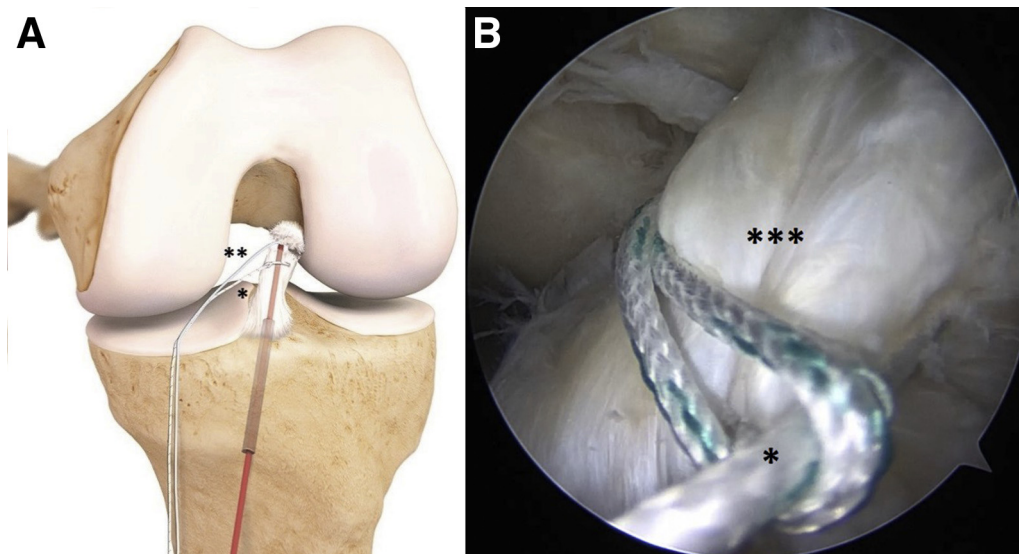
**Fig 4.** (A) Left knee frontal view. This image provided courtesy of Arthrex, Inc. © 2018. (B) Left cadaver knee, intra-articular view on the anterior cruciate ligament (ACL) stump and the suture passer. After placing the tubed shuttle wire (\*) through the tibia tunnel and the ACL stump (\*\*), a looped wire is passed through the midsubstance of the ACL stump with a suture passer (\*\*), forming a lasso around the distal ACL stump. Care is taken not to capture the tubed shuttle wire (which is still in the ACL tissue).

stump (Fig 4). Care is taken not to capture the tubed shuttle wire (which is still in the ACL tissue). The looped wire is retracted through the medial portal, forming a lasso around the distal ACL stump (Fig 5). A second looped wire can be placed if there is doubt about the grip on the distal stump or in case of a multibundle rupture.

#### Femoral Tunnel

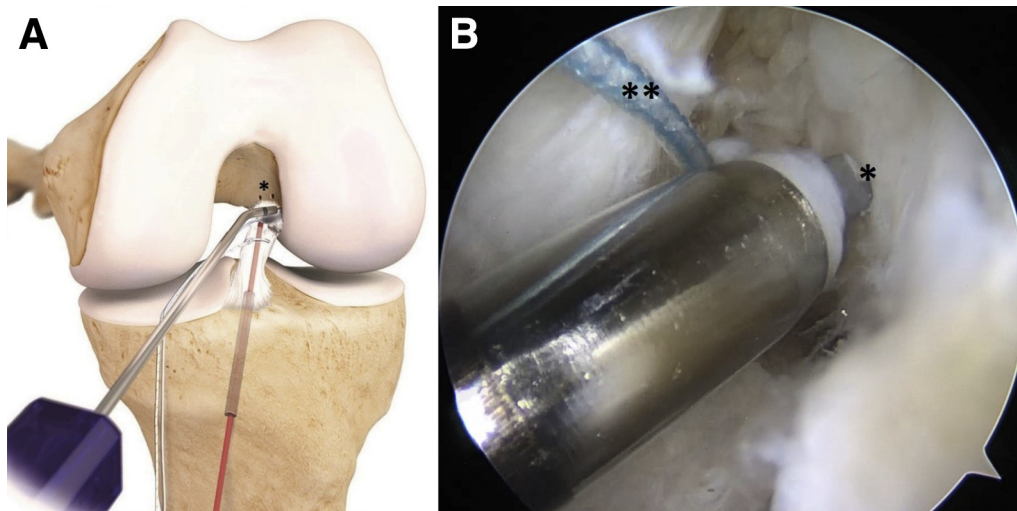
At the femoral attachment, microfracturing is performed (Fig 6). With a 3.5-mm drill (Drill Tip Guide Pin;

Arthrex), the femoral tunnel is drilled from the center of the femoral footprint inside out, with the knee fully flexed (Fig 7). A stab incision is made through the skin at the drill exit point, along the drill onto the femoral cortex, which facilitates tying the sutures on the femoral button later in the procedure. The end of the looped wire and the shuttle wire are placed through the eyelid at the end of the drill and passed through the joint, the femoral tunnel, and the skin. By pulling gently on the looped wire, the distal ACL stump



**Fig 5.** (A) Left knee frontal view. This image provided courtesy of Arthrex, Inc. © 2018. (B) Left cadaver knee, intra-articular view on the anterior cruciate ligament stump and the looped wire. The looped wire (\*), forming a lasso around the anterior cruciate ligament stump (\*\*\*), is retracted through the medial portal. The shuttle wire (\*\*) is taken from the tube and retracted through the medial portal as well.





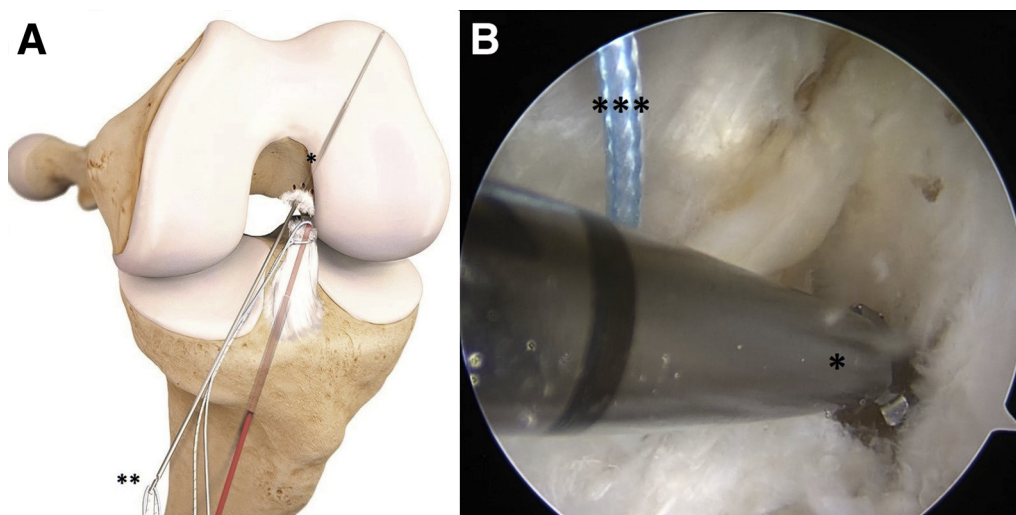
**Fig 6.** (A) Left knee frontal view. This image provided courtesy of Arthrex, Inc. © 2018. (B) Left cadaver knee, intra-articular view, microfracturing at the femoral attachment of the ACL. Microfracturing (\*) at the femoral attachment of the ACL is performed to improve the healing potential. Care is taken not to damage the shuttle wire (\*\*).

is repositioned against the femoral attachment (Fig 8). The shuttle wire is going to be the lead suture for the ISTR (*InternalBrace* ligament augmentation repair; Arthrex).

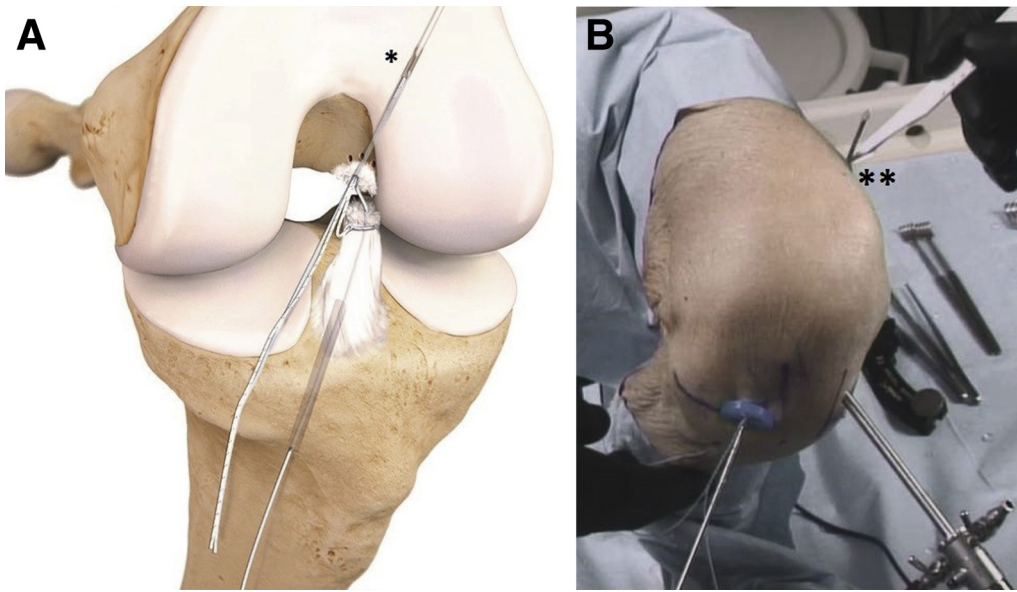
#### ISTR

A femoral button (Retrobutton/TightRope RT; Arthrex) loaded with a high-strength tape is transported proximally by the tibial end of the shuttle wire, through the tibial tunnel, the center of the ACL, and the femoral tunnel. The high-strength tape (FiberTape; Arthrex) is an ultra-high-strength 2-mm-wide tape consisting of a long-chain ultra-high molecular weight polyethylene core with a braided jacket of polyester and ultra-high molecular weight polyethylene. The button is flipped

on the femoral cortex, and the high-strength tape is advanced in the femoral tunnel by pulling the 2 tensioning strands, one at a time (Fig 9). The high-strength tape is kept on a slight tension until it is fixed, just below the tibial tunnel. After predrilling with a 4.5-mm drill and a 20-mm drill stop, followed by tapping, a 4.75-mm bone anchor (SwiveLock; Arthrex) loaded with both ends of the high-strength tape is placed with the knee in full extension (Fig 3). To avoid over-tightening, the high-strength tape is marked at the beginning of the screw of the bone anchor and repositioned in the eye of the bone anchor at the marked level, and finally the bone anchor is placed in the drill hole (Fig 10). Care is taken not to damage the hamstrings. The tibial drill hole is kept under direct vision to avoid



**Fig 7.** (A) Left knee frontal view. This image provided courtesy of Arthrex, Inc. © 2018. (B) Left cadaver knee, intra-articular view on the center of the femoral footprint; the starting point of the drill for the femoral tunnel. With a 3.5-mm drill (\*), the femoral tunnel is drilled from the center of the femoral footprint inside out, with the knee fully flexed. The looped wire and the shuttle wire (\*\*\*) will be passed through the femoral tunnel with the end of the drill (\*\*).



**Fig 8.** (A) Left knee frontal view. This image provided courtesy of Arthrex, Inc. © 2018. (B) Left cadaver knee, external frontal view. It is important to mobilize the tractus at the lateral femur just along the drill pin down to the lateral cortex with a stab incision (\*\*). Splitting the iliotibial band allows proper placement of the repair knot. The looped wire and the shuttle wire are passed from the anteromedial portal through the femoral tunnel with the end of the drill (\*). The tube from the shuttle wire is removed from the tibial tunnel.

superficial placement of the bone anchor in the bone or losing the position of the drill hole.

### ACL Repair

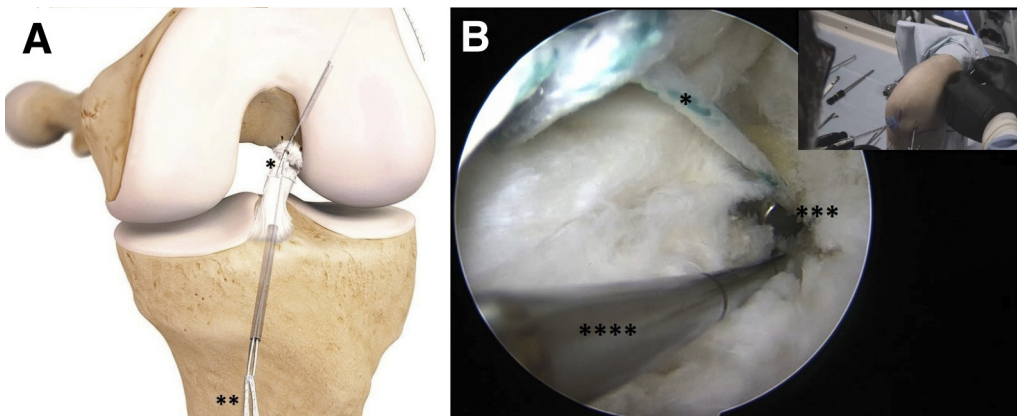
With the ISTR completed, we now focus on the ACL repair. The knee is positioned in 90° of flexion. The ruptured ACL fibers are gently tensioned with the looped wire using the cinch to approximate the distal stump to the femoral footprint. It is important for the distal stump to be in contact with the proximal stump; a gap is not acceptable. The looped wire is tied with the 2 tensioning

strands on the femoral button with the appropriate tension on the ACL. The remnants of the looped wire, tensioning strands, and high-strength tape are cut and removed (Fig 11).

[Video 1](#) shows the ACL ISTR repair technique on a left cadaver knee.

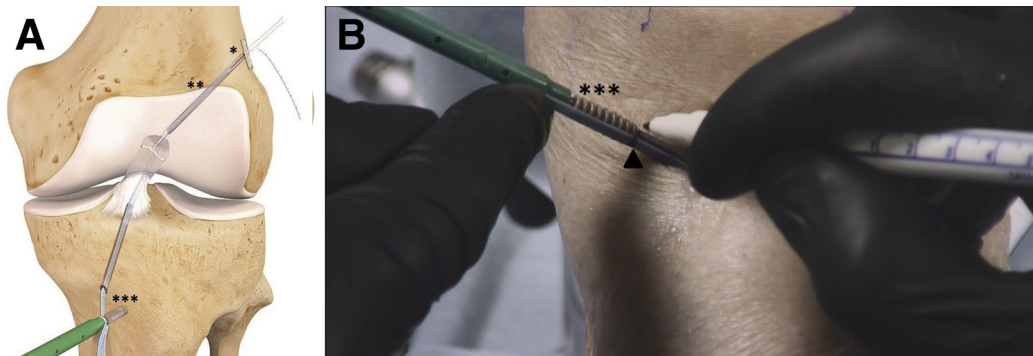
### Rehabilitation

The rehabilitation protocol can be compared with an accelerated ACL reconstruction protocol. The patients were allowed to fully weight bear with crutches as



**Fig 9.** (A) Left knee frontal view. This image provided courtesy of Arthrex, Inc. © 2018. (B) Left cadaver knee, intra-articular view of the femur button at the starting point of the femoral tunnel. By pulling gently on the looped wire (\*), the distal anterior cruciate ligament stump is repositioned against the femoral attachment. The shuttle wire (\*\*) is going to be the lead suture for the independent suture tape reinforcement. A femoral button (\*\*\*) loaded with a high-strength tape is transported proximally by the tibial end of the shuttle wire, through the tibial tunnel, the center of the ACL, and the femoral tunnel. A probe (\*\*\*\*) can be used to facilitate the passing of the button in the femoral tunnel.





**Fig 10.** (A) Left knee frontal view. This image provided courtesy of Arthrex, Inc. © 2018. (B) Left cadaver knee, external frontal view, marking of the high-strength tape. The button is flipped on the femoral cortex (\*), and the high-strength tape (\*\*) is advanced in the femoral tunnel by pulling the 2 tensioning strands, one at a time. The high-strength tape is being kept on a slight tension until it is fixed just below the tibial tunnel. A bone anchor (\*\*\*) loaded with both ends of the high-strength tape is placed with the knee in full extension. To avoid overtightening, the high-strength tape is marked at the beginning of the screw of the bone anchor (▲) and repositioned in the eye of the bone anchor at the marked level, and finally the bone anchor is placed in the drill hole. Care is taken not to damage the hamstrings.

required during the first weeks. Physical therapy focuses on early range of movement, muscle control, and restoration of function. This approach is facilitated by the limited pain and swelling, allowing accelerated early-phase rehabilitation. Patients were allowed to perform pivoting sports if the neuromuscular function had recovered; for most patients, this happened within 5 months. No brace was required.

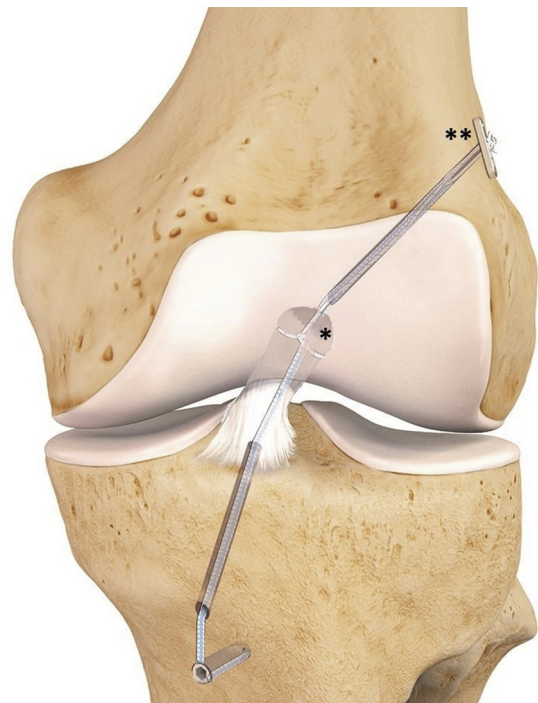
## Discussion

Compared with other ACL repair techniques, one of the key features of the ISTR technique is the secondary stabilizer. The ISTR reinforces the ACL and acts as a safety belt, encouraging natural healing of the ligament by protecting it during the healing phase and supporting early mobilization.<sup>3</sup> The ISTR technique is less invasive than ACL reconstruction; the 3.5-mm bone tunnels are about half the size of the reconstruction bone tunnels. In the case of a rerupture, a standard ACL reconstruction can still be performed as “no bridges are burned.” The native ACL is spared, providing proprioceptive properties, which could contribute to a shorter rehabilitation period. Furthermore, there is no hamstring or patella tendon harvesting comorbidity as no graft is needed (Table 1).

In a 1-year follow-up case series of 68 patients treated with the ISTR technique for an acute ruptured ACL, Mackay et al.<sup>3</sup> describe comparable findings with early results from ACL reconstruction, with the greatest improvements seen in return to sporting activity.

One limitation is that not all ACL ruptures can be repaired (Table 2). If there is a gap between the ruptured ends, the continuous flow of the synovial fluid hampers the formation of a stable fibrin-platelet clot between the ruptured ends of the ACL in which stable scar tissue can form. Over time the distal stump can retract, which makes it impossible to repair without leaving a gap

between the bundles.<sup>4</sup> If the stump is not retracted during this time, it can be found reattached on the posterior cruciate ligament or more anterior to the femoral origin. If the distal stump can be mobilized and brought back to its femoral origin and the tissue quality is sufficient, a repair can still be performed. The outcome of



**Fig 11.** Left knee frontal view. The ruptured ACL fibers are gently tensioned with the looped wire (\*) to approximate the distal stump to the femoral footprint with the knee in 90° of flexion. The looped wire is tied with the 2 tensioning strands on the femoral button (\*\*) with the appropriate tension on the anterior cruciate ligament. The remnants of the looped wire, tensioning strands, and high-strength tape are cut and removed. This image provided courtesy of Arthrex, Inc. © 2018

**Table 1.** Advantages and Disadvantages of Anterior Cruciate Ligament (ACL) Repair Using Independent Suture Tape Reinforcement

Advantages	Disadvantages
The native ACL is spared, providing proprioceptive properties and enhancing the revalidation.	Not all ACL ruptures can be repaired.
No donor harvesting morbidity.	Synthetic augmentation.
The independent suture tape reinforcement technique is less invasive than ACL reconstruction.	
In the case of rerupture, a standard ACL reconstruction can be performed.	

midsubstance (25%-75%) ACL repairs is significantly worse than that of proximal ruptures. Proximal ACL ruptures, with sufficient tissue quality and good contact between the ruptured ends, have the best outcomes.<sup>5</sup>

In the case of an acute (within 3 months) ruptured ACL, we start with an arthroscopic inspection of the ruptured ACL. If the rupture is not repairable, a graft is harvested and a standard ACL reconstruction is performed. Otherwise, the ISTR ACL repair is performed, which provides an environment in which the ruptured ACL can heal.

## References

1. Anderson MJ, Browning WM 3rd, Urband CE, Kluczynski MA, Bisson LJ. A systematic summary of

**Table 2.** Limitations of Anterior Cruciate Ligament (ACL) Repair Using the Independent Suture Tape Reinforcement Technique

There is a time limit of approximately 3 months postrupture for the surgery.
The ACL stump has to be of good tissue quality and not retracted.
No gap between the ruptured ends is allowed after the repair.
Outcome of midsubstance (25%-75%) ACL repairs are significantly worse.
No mid- to long-term follow-up results are published.

systematic reviews on the topic of the anterior cruciate ligament. *Orthop J Sports Med* 2016;4. 2325967116634074.

2. Taylor SA, Khair MM, Roberts TR, DiFelice GS. Primary repair of the anterior cruciate ligament: A systematic review. *Arthroscopy* 2015;31:2233-2247.
3. Mackay GM, Blyth MJ, Anthony I, Hopper GP, Ribbans WJ. A review of ligament augmentation with the InternalBrace: The surgical principle is described for the lateral ankle ligament and ACL repair in particular, and a comprehensive review of other surgical applications and techniques is presented. *Surg Tech Int* 2015;26: 239-255.
4. Murray MM, Martin SD, Martin TL, Spector M. Histological changes in the human anterior cruciate ligament after rupture. *J Bone Joint Surg Am* 2000;82: 1387-1397.
5. van der List JP, DiFelice GS. Preservation of the anterior cruciate ligament: A treatment algorithm based on tear location and tissue quality. *Am J Orthop (Belle Mead NJ)* 2016;45:E393-E405.